

## **“Screening System For Early Detection of Diabetic Retinopathy”**

Mr.Sudhakara Reddy M<sup>1</sup>, Jayashree B S<sup>2</sup>,Kavya S<sup>3</sup>,Lavanya K E<sup>4</sup>, Vikas Reddy P<sup>5</sup>

<sup>1</sup> *Asst Professor, Department of Computer Science and Engineering, Nagarjuna College of Engineering and Technology, Bangalore, India.*

<sup>2,3,4,5</sup> *B.E. Students, Department of Computer Science and Engineering, Nagarjuna College of Engineering and Technology, Bangalore, India.*

### **1. ABSTRACT**

The purpose of this paper is to conduct a review of various literatures in order to conduct a comprehensive study. Diabetic Retinopathy (DR) research is being conducted, and various machine learning techniques are being used to detect DR. Diabetic Retinopathy (DR) is an eye disease that occurs in people who have diabetes and can harm the retina of the eye, resulting in total visual impairment. As a result, detecting diabetics is critical.

Our goal is to use machine learning classifying algorithms to detect the presence of diabetic retinopathy. As a result, we attempt to summarise the various models and techniques used, as well as the methodologies employed, and analyse the accuracies and results. It will tell us which algorithm will be more appropriate and accurate for prediction.

### **2. INTRODUCTION**

Diabetes is a metabolic disease in which an individual's blood glucose level is elevated, either because the body does not produce enough insulin or because the cells are unable to use the insulin that is produced

effectively. Diabetes is associated with damage to the small blood vessels of the retina, resulting in diabetic retinopathy (DR).

Diabetic retinopathy can cause the blood vessels within the retina to leak fluid or bleed, resulting in blurred or impaired vision. In its later stages, new abnormal blood vessels proliferate on the retina's surface, causing scarring and cell loss within the retina. Diabetes retinopathy is one of the most common complications of diabetes.

It is a serious and widespread disease. Because the risk of the disease increases with age, diabetics in their middle and older years are more vulnerable to Diabetic Retinopathy. Laser treatment can be used to prevent visual impairment or blindness in people with DR whose eyesight is at risk. However, there is currently no treatment that can restore vision that has already been lost.

Detecting DR is a time-consuming and manual process that necessitates the examination and evaluation of digital colour fundus photographs of the retina by a trained clinician. As a result, detecting DR at an early stage is critical.

### **3. LITERATURE SURVEY**

The principles of DR were studied in this paper, which included the stages, causes, symptoms, and risks associated with it, as well as basic concepts of the human eye and body related to DR. This study intends to point a researcher in the right direction in order to propose a new DR detection method.

The main cause of DR, according to this study, is an unusual increase in glucose level. The first signs of DR are microaneurysms, which are tiny capillary dilations. According to the study, DR progression causes neovascularization, macular edoema, and exudates, as well as the cotton wool spot, which causes retinal segregation in the later stages.

The four stages of DR were labelled as follows:

1. Mild Non-proliferative Retinopathy: This is the first stage in which microaneurysms form.
2. Moderate Non-proliferative Retinopathy: As the disease progresses, a small number of blood vessels that supply the retina become blocked.
3. Severe Non-proliferative Retinopathy: More blood vessels become blocked, reducing blood flow to the retina. These areas transmit signals.
4. Proliferative Retinopathy: In this advanced stage, the retina's signals for nourishment cause the formation of new blood vessels. This is known as proliferative retinopathy. These new blood vessels are

unusual and delicate. These blood vessels do not cause symptoms or vision loss on their own. Because of their thin and weak walls, they can leak blood, causing severe vision problems.

The retinal image is a very important diagnostic tool that assists ophthalmologists in performing diagnosis, treatment, and screening of various epidemic eye diseases such as DR.

They claim that there are no DR symptoms or warning signs in the early stages. Detection of the first stage, Non proliferative diabetic retinopathy (NPDR), is possible.

Fluorescein angiography is used to see the back of the eye in people who have low vision. Because the new blood vessels are fragile, neovascularization at the back of the eye can burst, bleed, and blur vision in the second stage. When it happens for the first time, it isn't too bad; it just leaves a few spots in your vision.

A doctor will see cotton wool spots, flame haemorrhages, and dot-blot haemorrhages during a funduscopy exam.

Objective:

- Develop a robust solution to for predicting the Diabetic Retinopathy from a given sample input image
- Train the model against enough data sets to maintain the accuracy level above 90%

- Optimize the model to rise the accuracy level even further
- Provide data visualization features for the customers to get more valuable insight of the patient health
- Expose the solution over the cloud as a service so that the solution can be re-usable by any third party applications

#### **4. DIABETIC RETINOPATHY**

It depicts the presence and extent of features such as hard exudates, cotton wool spots, micro aneurysms, or hemorrhage's caused by fluid and blood leakage from blood vessels. Normal DR, NPDR, and PDR are the three types of DR. Diabetic retinopathy is classified into two types: non proliferative (NRDR) and proliferative (PDR).

The presence of micro aneurysms characterizes the early stage of the disease, which is no proliferative. As the disease progresses, the retina loses oxygen and new blood vessels form, causing vision to become cloudy. There are three types of NPDR: mild NPDR, moderate NPDR, and severe NPDR. Micro aneurysms are small areas of balloon-like swellings in the retina's tiny blood vessels that occur in mild NPDR. Micro aneurysms are small areas of balloon-like swellings in the retina's tiny blood vessels that occur in mild NPDR.

As the disease progresses, some blood vessels that nourish the retina become blocked, resulting in moderate NPDR. The next stage is severe NPDR, which affects a

large number of people. More blood vessels are becoming clogged.

#### **5. TECHNIQUES AND MATERIALS**

The evaluation of the automated classification method of diabetic retinopathy was conducted in this paper using a set of 94 images captured by a retinal fundus camera and stored in JPG photograph format files with a size of 1500 1152 pixels at 24 bits pixel length.

It depicts a proposed methodology in which an image is obtained from a retinal fundus data set and then pre-processing techniques are applied to the retinal image. Following that, morphological operations are carried out to identify exudates and micro-aneurysms. Finally, the severity or grade of abnormality is determined using multiclass SVM and KNN classifiers. The input images for the given methodology are taken from MESSIDOR and Diabetic DB1.

#### **6. PROPOSED SYSTEM**

##### **6.1 Problem Statement**

“To detect diabetic retinopathy using machine learning.”

##### **6.2 Problem Elaboration**

Diabetic retinopathy (DR) is a disease that causes blindness in diabetics. Currently, in order to detect DR, medical personnel must manually examine images of the retina captured using the Fundus photography technique. This takes a long time. We proposed a model to detect DR using

machine learning techniques such as neural networks to automate and improve this detection process.

Memory and Time efficient  
 Solution made available to public

### 6.3 Proposed Methodology

In this project, CNN-based image processing is used to identify whitish lesions, cotton wool spots, and hard exudates associated with DR, utilising knowledge from Computer Science and Biomedical Engineering.

Based on the importance of pixel counts, the image of the patient's eye under investigation is classified as Diabetic Retinopathic or Non-Diabetic Retinopathic.

This technique has the potential to be useful for detecting DR early without the need for an expert doctor, saving both time and money.

During this project, we will be performing the following tasks:

- Use the PSNR, MSE, and SSIM image quality metrics,
- Process images using OpenCV,
- Convert between the RGB, BGR, and YCrCb color spaces,
- Build deep neural networks in Keras,
- Deploy and evaluate the SRCNN network

#### Advantages

- i. Overcomes the drawbacks of the existing researches
- ii. Proven High accuracy

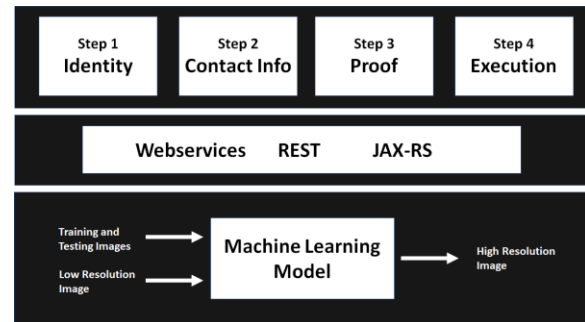


Fig:- Machine Learning model.

## 7. IMPLEMENTATION

### Training, Testing, and Saving the model -

This module implements the CNN (Convolutional Neural Network) algorithm and the PyTorch libraries for developing the machine learning model to improve the resolution of the images. This model uses numerous training images for learning purpose. The training is done by purposefully reducing the quality of the training images and then making the model to learn how the low resolution image and the high resolution images looks like. This module also performs the testing of the model to ensure the model is good enough to work on the new images in the further modules. The model after undergoing training and testing process, will be saved on the local disk.

### Loading the model to work on new dataset

- In this module, the model which is saved

on local disk in the previous module will be loaded back into the processor memory.

The library we are using to load and save the model is „Torch“. What we get after loading the trained model is the component which already has the intelligence to improve the resolution of images.

This model is then provided with an input image to improve the resolution. By this approach of loading and saving the model to and from the local disk, we save a really lot of time when processing the real time images.

**Webservice Implementation** - In this module, we implement the web services to expose the model to the outside world. We expose an HTTP post API against which the user can upload a low resolution image and request for executing the model.

The webservice API upon receiving the request from the client, will store the uploaded image inside the „/home /Ubuntu /input“ location of the amazon EC2 machine and then it invokes the SR.py program by specifying this input folder. The output image will be stored inside „/home /ubunut /output“ location inside amazon EC2 machine.

To download this image into user’s machine, the web service will provide another URL as a response by clicking on which the image gets downloaded to the client’s machine

**Third party application** - In this module, the sample third party application has been implemented to demonstrate the usage of the

web services to the customers. In this application, we implement four steps

Step 1: User Identity: We collect the user’s first name and the last name.

Step 2: Contact Information: We collect the email ID and mobile number of the client.

Step 3: Proof: We will send an OTP to customer and ask them to enter it to prove the identity.

Step 4: Execution: User uploads an input image here and clicking on Run button will invoke the web service implemented in the previous module. The result of the analysis will then be displayed back on the result screen.

## 8. RESULTS

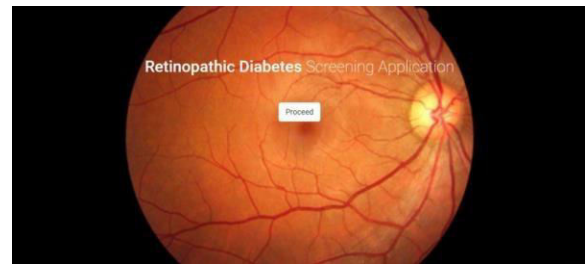


Fig:-Home page.

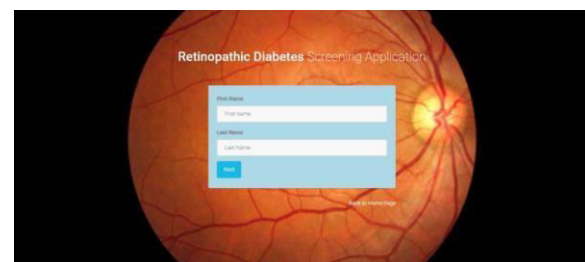


Fig:- Form for inserting first name and last name.



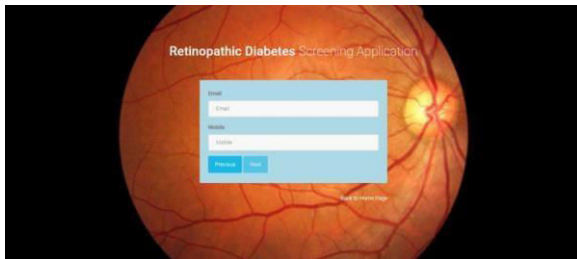

Fig:- Form for inserting Email and Mobile.

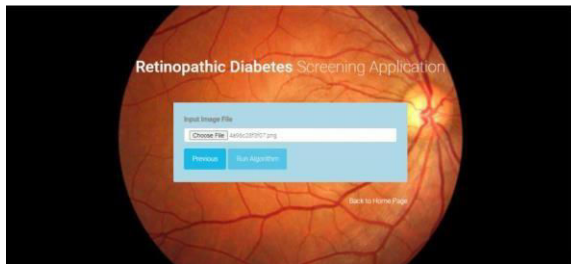

Fig:- Insert Image file.

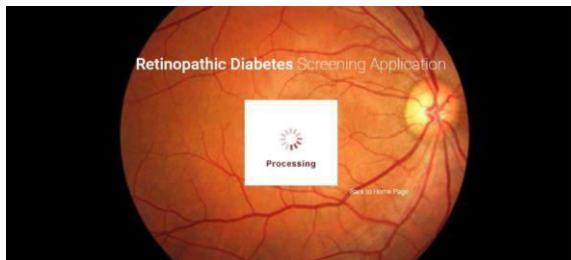

Fig:- Processing.

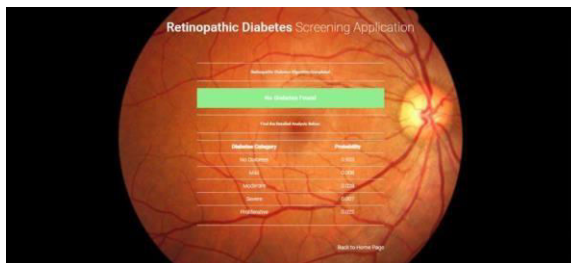

Fig:- Final results for input image.

## 9. CONCLUSION

In this project, CNN based image processing is used which exploits the knowledge of Computer Science and Biomedical Engineering to identify whitish lesions, cotton wool spots and hard exudates associated with DR. The picture of the patient's eye under investigation is graded as a Diabetic Retinopathy eye or a Non-Diabetic Retinopathic eye based on the importance of pixel counts.

This technique has the potential to be useful for the early detection of DR without the need for an expert doctor, saving both time and money.

## BIBLIOGRAPHY

- [1] Wan Mustafa, Aimi Abdul-Nasir, Haniza yazid, "Diabetic Retinopathy (DR) on Retinal Image", IOP publishing
- [2] Marco Alban, Tanner Gilligan, "Automated Detection of Diabetic Retinopathy using Fluoresce in Angiography Photographs"
- [3] Akara Sopharak a\* , Matthew N. Dailey b ,Bunyarit Uyyanonvara a Sarah Barman c ,Tom Williamson d , Khine Thet Nwe b and Yin Aye Moe b, "Machine learning approach to automatic exudate detection in retinal images from diabetic patients"
- [4] Kanika Verma, Prakash Deep and A. G. Ramakrishnan, Senior Member, IEEE, "Research Paper 4:Detection and

Classification of Diabetic Retinopathy using Retinal Images”

distributed database: the Messidor database,” Image Analysis Stereology, vol. 33, no. 3, pp. 231–234, Aug. 2014.

[5] Wong Li Yun and Muthu Rama Krishnan Mookiah Department of Electronics and Computer Engineering, Ngee Ann Polytechnic, Singapore 599489 , “Detection of Diabetic Retinopathy Using K-Means Clustering and SelfOrganizing Map ”

[6] Enrique V. Carrera , Ricardo Carrera, Andres Gonzalez, “Automated detection of diabetic retinopathy using SVM ”

[7] Salman Sayed, Dr. Vandana Inamdar , Sangram Kapre , “Detection of Diabetic Retinopathy using Image Processing and Machine Learning”

[8] Suvajit Dutta, Bonthala CS Manideep, Syed Muzamil Basha, Ronnie D. Caytiles1 and N. Ch. S. N. Iyengar, “Classification of Diabetic Retinopathy Images by Using Deep Learning Models”

[9] Alex Krizhevsky, Ilya Sutskever, and Geoffrey E. Hinton. Imagenet classification with deep convolutional neural networks. In F. Pereira, C. J. C. Burges, L. Bottou, and K. Q. Weinberger, editors, Advances in Neural Information Processing Systems 25, pages 1097– 1105. Curran Associates, Inc., 2012.

[10] Christian Szegedy, Wei Liu, Yangqing Jia, Pierre Sermanet, Scott Reed, Dragomir Anguelov, Dumitru Erhan, Vincent Vanhoucke, and Andrew Rabinovich. Going deeper with convolutions, 2014.

[11] E. Decenci,ere, X. Zhang, G. Cazuguel, B. Lay, B. Cochener, C. Trone, P. Gain, R. Ordonez, P. Massin, A. Erginay, B. Charton, and J.-C. Klein, “Feedback on a publicly